

See discussions, stats, and author profiles for this publication at: <https://www.researchgate.net/publication/51297166>

Examination of the validity of the hierarchical model of neuropathological staging in normal aging and Alzheimer's disease

Article in *Acta Neuropathologica* · February 1998

DOI: 10.1007/s004010050780 · Source: PubMed

CITATIONS

63

READS

28

10 authors, including:



Felicia Huppert

University of Cambridge

196 PUBLICATIONS 16,141 CITATIONS

[SEE PROFILE](#)



Carol Brayne

University of Cambridge

1,103 PUBLICATIONS 90,680 CITATIONS

[SEE PROFILE](#)



Elizabeta B Mukaetova-Ladinska

University of Leicester

197 PUBLICATIONS 9,809 CITATIONS

[SEE PROFILE](#)



Thomas Arendt

University of Leipzig

436 PUBLICATIONS 15,686 CITATIONS

[SEE PROFILE](#)

Some of the authors of this publication are also working on these related projects:



Blood biomarkers for dementia [View project](#)



Understanding Alzheimer's Disease [View project](#)

REGULAR PAPER

H.-J. Gertz · J. Xuereb · F. Huppert · C. Brayne
 M. A. McGee · E. Paykel · C. Harrington
 E. Mukaetova-Ladinska · T. Arendt · C. M. Wischik

Examination of the validity of the hierarchical model of neuropathological staging in normal aging and Alzheimer's disease

Received: 15 January 1997 / Revised: 1 July 1997 / Accepted: 14 July 1997

Abstract The neuropathological staging model of Alzheimer's disease proposed by Braak and Braak [Acta Neuropathol (1991) 82:259] requires that the evolution of neurofibrillary pathology follows a predictable pattern that can be ordered in a regular regional hierarchy. We have operationalized the neuropathological staging system to permit testing of its validity. Forty-two cases were derived from an epidemiological study of cognitive function in an elderly population for which post-mortem brain tissue was collected. Cases with neuropathological diagnoses other than Alzheimer's disease and normal aging were excluded. Neurofibrillary tangle counts were determined in all cortical laminae and regions used for staging. There was a significant correlation between the overall extent of neurofibrillary pathology and the number of re-

gions affected. There were frequent order violations in the proposed hierarchy: 19 instances (45%) involving entorhinal and transentorhinal cortices, and 16 instances (38%) involving CA1 of hippocampus and entorhinal cortex. Only 6 out of 42 cases conformed in all regions to the expected hierarchy. Nevertheless, 90% of the cases had 2 order violations or less, supporting the approximate validity of the hierarchy.

Key words Neuropathological staging · Alzheimer's disease · Neurofibrillary tangles · Pathological hierarchy

Introduction

In their original descriptions both Alzheimer [1] and Perusini [20] regarded the neurofibrillary tangle (NFT) as a novel pathological structure that was specifically associated with a dementing disorder of presenile onset. In his subsequent study, Simchowicz [22] emphasized the coexistence of plaques and NFTs, and hence the overlap with the pathology of normal aging as previously described by Blocq and Marinesco [3]. Gellerstedt emphasized the tendency of the hippocampal structures to develop neurofibrillary pathology [12]. In a series of non-demented cases over the age of 70 years, Hirano and Zimmerman [14] found that 70% had NFTs in layer pre- α of the entorhinal cortex and/or in CA1 of hippocampus. In Alzheimer's disease (AD) the neurofibrillary pathology can be observed in the isocortex [23] and, in severe cases, primary sensory areas of the neocortex can be involved [10].

Based on an extensive post-mortem series, Braak and Braak [7] proposed that the evolution of neurofibrillary pathology follows a predictable pattern in which six stages could be discerned. The first two stages are characterized by the presence of NFTs in the pre- α layer of the transentorhinal cortex, occasional NFTs in CA1, and none in neocortical regions. Stages 3 and 4 (limbic stages) are characterized by more severe neurofibrillary pathology in transentorhinal and entorhinal cortices and in CA1 of hippocam-

H.-J. Gertz (✉)
 Psychiatrische Klinik der Universität Leipzig, Liebigstrasse 22,
 D-04103 Leipzig, Germany

J. Xuereb · C. Harrington · E. Mukaetova-Ladinska
 C. M. Wischik
 Cambridge Brain Bank Laboratory, MRC Centre, Hills Road,
 Cambridge, UK

F. Huppert · E. Paykel · C. M. Wischik
 Department of Psychiatry,
 University of Cambridge Clinical School, Hills Road,
 Cambridge, UK

C. Brayne
 Department of Community Medicine,
 University of Cambridge Clinical School, Robinson Way,
 Cambridge, UK

J. Xuereb
 Department of Pathology, University of Cambridge Clinical
 School, Hills Road, Cambridge, UK

M. A. McGee
 MRC Biostatistics Unit, Institute of Public Health,
 University of Cambridge Clinical School, Robinson Way,
 Cambridge, UK

T. Arendt
 Paul-Flechsig-Institut für Hirnforschung, Leipzig, Germany

pus, together with the appearance of NFTs in association neocortex. In the isocortical stages (stages 5 and 6) there are numerous NFTs in all neocortical association areas and also in the primary sensory areas such as the striate cortex.

This staging model implies a regular regional hierarchy in the evolution of neurofibrillary pathology in the brain. Braak and Braak [7] proposed the following hierarchical anatomical sequence in the cortex: the transentorhinal lamina pre- α of the transentorhinal cortex (lamina principalis externa, layer II), the lamina pre- α of the entorhinal cortex, the hippocampal area CA1, the lamina pri- α of the entorhinal cortex (lamina principalis interna layer IV), the association cortex together with lamina pre- β of the entorhinal cortex (layer III), the parastriate and the striate cortex (Brodmann area 18 and 17). Subcortical nuclei are also included in this staging system, but these are not considered in the present study. According to the hierarchical model, regions that appear earlier in this list have both more NFTs and are affected in less severe cases than regions that appear later.

To test the validity of this model we have attempted to operationalize it in quantitative and qualitative terms. Cases were derived from an epidemiological study of cognitive function in an elderly population in the Cambridge area in which brain tissues were collected irrespective of clinical severity of cognitive impairment [19].

Materials and methods

The 50 brains analyzed initially were a subset of brains obtained from a population based sample of elderly people in the Cambridge City over-75 Cohort (CC75C). The clinical methods used have been published in detail elsewhere [18, 19]. All subjects included here had been prospectively clinically assessed with the Camdex interview [21]. Data about the utility of the staging model as a diagnostic tool have been reported elsewhere [13].

Brains obtained post-mortem were cut in the sagittal plane. One cerebral hemisphere was dissected, macroscopically examined and frozen. The other half of the brain was fixed in formalin for at least 3 weeks. For diagnostic purposes, blocks for paraffin embedding were taken from the hippocampus at the level of the lateral geniculate body, from the entorhinal cortex at the level of the mammillary body, from the frontal, temporal, parietal and occipital isocortices, from the basal ganglia, thalamus and two levels of the midbrain, and from pons, medulla and cerebellum.

Sections (7 μ m thick) were cut and stained with hematoxylin and eosin (H&E) to assess nerve cell loss, gliosis, and ischemic change; and congo red to assess vascular amyloid deposits. The silver staining method of Campbell et al. [8] and immunohistochemistry with a monoclonal antibody against β /A4 (donated by Dr. M. Landon, Department of Biochemistry, Nottingham University, UK) were used to demonstrate β -amyloid. A monoclonal antibody against phosphorylated tau protein (11.57) [16] was used to label NFTs. The neuropathological assessment was performed blind to the clinical data.

Morphometry and staging procedure

Eleven laminae/areas were selected for the quantification of NFTs for this study: the transentorhinal lamina pre- α , the entorhinal laminae pre- α , pre- β , and pri, the hippocampal area CA1, the frontal

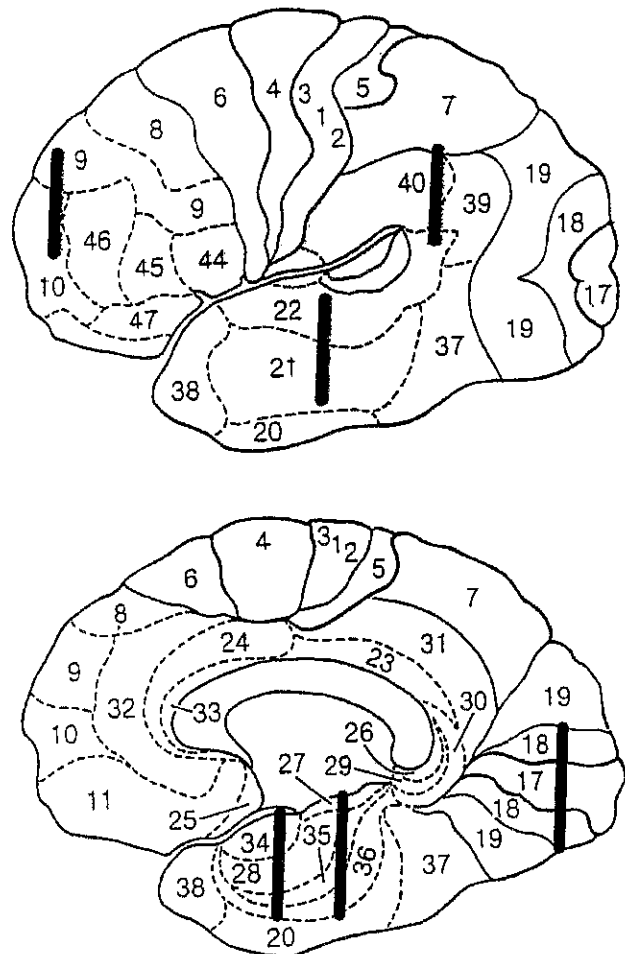


Fig. 1 Simplified diagram of the cerebral cortex with Brodmann areas. Bars mark where blocks were taken for qualitative and quantitative staging procedure

lobe (Brodmann area 9/10), the inferior parietal lobule (Brodmann area 39/40), the temporal lobe including superior and middle temporal gyrus (Brodmann area 21/22), and the parastriate and striate cortex (Brodmann area 18 and 17) (Fig. 1). The quantification of neurofibrillary pathology in the neocortex was based on counting six randomly chosen fields per section next to a sulcus: two fields each at the crest, the side and the base of the sulcus. The fields were chosen randomly using a low-power dissection microscope in which NFTs could not be resolved, and marked for subsequent morphometry for which a standard transmission light microscope was used at $\times 100$ magnification. In those instances where no NFTs were detected in any of the randomly chosen areas, a further area representing the maximally affected field was included as an additional measure to calculate the mean. This had the effect of minimizing the possibility of failure to detect NFTs when these were extremely sparse. Counts were undertaken with the help of an ocular grid covering a field of 0.9×0.9 mm². To establish agreed inter-observer criteria, 17 complete cases which were not part of this series were examined jointly by two of the investigators (H.J.G. and J.H.X.) applying the full protocol. Inter-observer reliability for NFT counts in this study was examined in 34 sections representative of all neuropathological stages and was found to be high (Kendall's $\tau = 0.85$).

In addition to morphometric analysis, each case was graded independently by H.J.G. and J.H.X. using the staging criteria proposed by Braak and Braak [7]. Where there was disagreement, the cases were discussed in detail until agreement was achieved.

Statistical analysis

The regional hierarchy analyzed here includes eight regions (Fig. 1) where the association cortex includes the parietal, frontal and posterior temporal lobes. The hierarchy was analyzed both qualitatively (absence versus presence) and quantitatively (mean count per field) by considering the number of order violations. For the qualitative measures, an order violation was defined as an instance in which NFTs were present in a region occupying a lower place in the proposed hierarchy than the region immediately preceding it. For quantitative measures, order violations were defined as instances in which more NFTs were seen in a region occupying a lower place in the proposed hierarchy than the region immediately preceding it.

The two-sample *t*-test, Fisher's exact test, Pearson's correlation coefficient and Kendall's tau were used. The statistical packages SPSS for Windows (SPSS, Chicago, Ill.) and SAS (Cary, N.C.) were used.

Results

Clinicopathological description of cases studied

Of 50 cases initially selected on the basis of availability of brain tissues and appropriate clinical information, 8 were

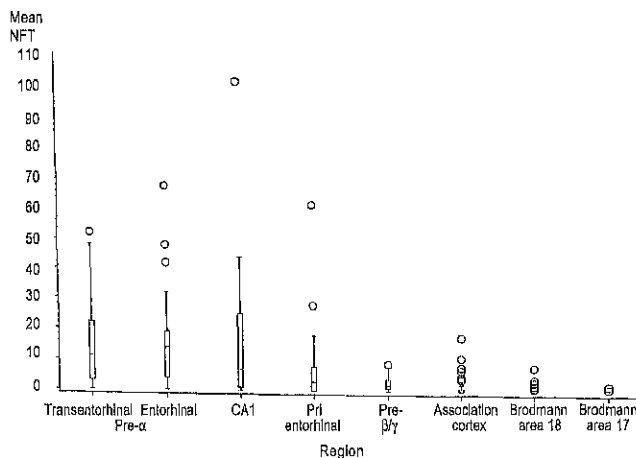


Fig. 2 Box-whisker plot of mean NFT counts in cortical areas sorted according to the proposed staging hierarchy [7]. The association cortex value is the mean of mean counts for temporal, frontal, and parietal cortex. The lower boundary of box is the 25th percentile and the upper boundary is the 75th percentile. The horizontal line inside box represents the median ($n = 42$) (NFT neurofibrillary tangle)

Table 1 Number of violations in the proposed neuropathological hierarchy according to presence or absence pathology (type 1), mean regional NFT count (type 2) and maximum field NFT count (type 3). Regions expected to have less pathology are indicated first

Regions compared	Type 1		Type 2		Type 3	
	<i>n</i>	(%)	<i>n</i>	(%)	<i>n</i>	(%)
Pre- α of entorhinal – pre- α of transent.	1	(2.3)	19	(45.2)	24	(57.1)
Hippocampus – pre- α of entorhinal	1	(2.3)	16	(38.0)	12	(28.5)
Pri of entorhinal – hippocampus	1	(2.3)	6	(14.2)	8	(19.0)
Pre- β/γ – pri of entorhinal	5	(11.9)	10	(23.8)	6	(14.2)
Association cortex – pre- β/γ	2	(4.7)	6	(14.2)	13	(30.9)
Brodman area 18 – association cortex	0	(0.0)	0	(0.0)	1	(2.3)
Brodman area 17 – Brodmann area 18	0	(0.0)	0	(0.0)	2	(4.7)
Total	10		57		66	

excluded from the present study because of vascular pathology. Presence of vascular pathology was defined according to the criteria of Chui et al. [9]. The remaining 42 cases included no cases with a neuropathological diagnosis other than normal aging or AD. The mean age at death was 89.1 years (SD 3.7, range 81–98 years). There were more females ($n = 27$) than males ($n = 15$). There was no correlation between age and NFT count in any brain region.

The extent of deviation from the hierarchical model used in the neuropathological staging

NFTs were detected in at least two brain regions in each case. The regional NFT counts are shown in Fig. 2. As can be seen, there is a general tendency for NFT counts to decrease according to the sequence predicted by Braak and Braak [7]. As expected, the medial temporal regions were much more severely affected than isocortical brain regions.

Although there was an overall agreement between the observed and predicted regional rank order (Fig. 2), a significant proportion of cases showed order violations which could be defined either in qualitative or quantitative terms. Following the definition for a qualitative order violation (see materials and methods), 33 cases (79%) showed no order violation from the hierarchy. There were only 10 out of possible 350 order violations, and half of these involved the pri region of entorhinal cortex and the pre- β/γ region (Table 1, column 1).

Following the definition for a quantitative order violation (see materials and methods), only 6 cases (14%) conformed entirely to the hierarchy. In contrast to the qualitative measure, the majority of these order violations in mean NFT counts emerged from comparisons between pre- α of transentorhinal and pre- α of entorhinal cortices ($n = 19$), and between pre- α of entorhinal cortex and CA1 of hippocampus ($n = 16$). Quantitative order violations were also seen in the pri and pre- β/γ regions ($n = 10$) involved (Table 1, column 2). The quantitative data was also analyzed in terms of maximally affected fields (Table 1, column 3). The anatomical distribution of order violations was similar, but in this analysis more order violations involving association cortex were detected ($n = 13$, 31%).

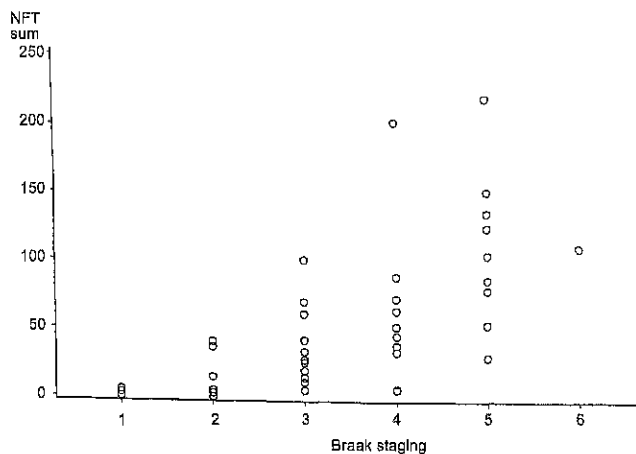


Fig. 3 Relationship between the sum of means for the regions indicated in Fig. 1 and neuropathological stage

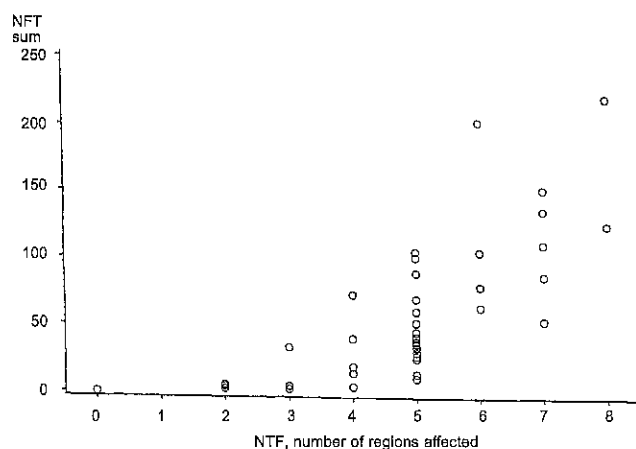


Fig. 4 Relationship between the sum of means for the regions indicated in Fig. 1 and the number of areas affected with neurofibrillary pathology

Validation of the basic assumptions of the staging model

An essential prediction of the staging model is that progression to a more advanced stage judged qualitatively is associated with an overall increase in the quantitative severity of pathology [7]. There was a statistically significant positive correlation between the sum of mean NFT counts from all brain regions and the neuropathological stage (Kendall's tau = 0.59, $P < 0.0001$; Fig. 3). Similarly, there was a significant positive correlation between the number of areas affected and the neuropathological stage (Kendall's tau = 0.66, $P < 0.0001$; data not shown). Most importantly, as shown in Fig. 4, there was a clear positive correlation between the sum of mean NFT counts in all brain regions and the number of brain regions affected (Kendall's tau = 0.67, $P < 0.0001$).

Discussion

In morphological studies of AD it is of particular importance to avoid artificial dichotomies by excluding borderline cases. In this study, only 45% of the cases were at the neuropathological extremes defined by Braak and Braak [7] (21% at stages 1 and 2, and 24% at stages 5 and 6), while the remaining 55% were at the intermediate stages 3 and 4. These latter cases are potentially the most informative for understanding the transition from normal to pathological aging. This distribution was achieved using a community sample defined in the course of prospective epidemiological studies of cognitive decline of the aging population. The only inclusion criteria were those of the original epidemiological studies [18, 19], availability of brain tissues and appropriate prospective clinical data.

In the present study we have sought to determine whether the neuropathological staging system proposed by Braak and Braak [7] can be validated by quantitative and qualitative analysis of the regional hierarchy in neurofibrillary pathology. The unstated assumption of the staging system is that the progression of pathology can be described systematically in two dimensions: number of regions affected and number of NFTs in the affected regions. There is no *a priori* reason to expect that an overall increase in the NFT count in the brain should be associated necessarily with an increase in the number of regions affected. At least theoretically, neurofibrillary pathology could remain relatively confined anatomically. There are three possible statistical correlations which test the validity of the underlying staging axiom: stage versus NFT count, stage versus number of regions affected, NFT count versus number of regions affected. In fact, all three correlations were statistically highly significant. Therefore, progression of neurofibrillary pathology does indeed occur in two dimensions, NFT count and number of regions, and relatively stable combinations of these parameters can be defined as stages.

We report that in 90% of the cases we have studied, the extent of neurofibrillary pathology in the brain regions used for the neuropathological staging can be considered to conform approximately to the expected hierarchy of vulnerability, provided that two order violations or less are allowed. The frequency of order violations was greatest in the allocortical regions, where the pathology would be expected to be most severe in advanced cases. It is possible that order violations occurring in these regions could be explained in part by transfer of NFTs from intracellular to extracellular compartments, associated with loss of the epitopes used in this study for immunohistochemical detection of NFTs [4–6, 15]. This is unlikely to provide an explanation for order violations involving the association cortex. These were detected more readily when the analysis was carried out in terms of maximally affected fields. This parameter could be affected by clustering of pathology in instances where no NFTs were initially detected, resulting in a lowering of the threshold for detection of neurofibrillary pathology in association cortex.

The existence of a regular neuroanatomical hierarchy in the evolution of neurofibrillary pathology presents difficulties for formulating a theory of the pathophysiology of dementia in terms of any particular brain region. Paradoxically, this is due to the validity of the hierarchical model itself, because it carries with it the implication that progression of neurofibrillary pathology into neocortical regions is necessarily associated with more advanced pathology in allocortex. It then becomes difficult to decide whether to attribute dementia to involvement of the neocortex, or to progression of allocortical pathology, or to a combination of both. Further studies which address the functional consequences of neocortical pathology as well as NFT-mediated pyramidal cell loss in the allocortex are needed to understand better the pathophysiology of clinical dementia in AD.

In a recent study using the same series of cases, the utility of the staging model as a neuropathological diagnostic instrument was found to be limited [13]. Although the transition from stage 3 to stage 4 was associated in a statistically significant manner with the appearance of dementia as defined by CAMDEX criteria [21], there was a considerable overlap. The transition from stage 3 to stage 4 is marked by the appearance of NFTs in the association neocortex [7]. In our previous study, as in others, the only brain region in which NFT counts provided a statistically significant marker for the appearance of dementia was the association cortex [2, 11, 12, 17, 24]. Therefore, the diagnostic value of the stage 3 to 4 transition would appear simply to reaffirm the significance of neocortical pathology in detection of cases with clinical dementia.

Acknowledgements This work was supported in part by the Medical Research Council (UK) grants to C.M.W., C.R.H., J.H.X., E.S.P., F.H., and C.B. E.B.M.L. was supported by the MRC. C.H. was supported by the Newton Trust Trinity College. H.J.G. and T.A. were supported by the Interdisziplinäres Zentrum für Klinische Forschung, Leipzig, Germany. We would like to express our gratitude to A. O'Sullivan and R. Hazelman for assistance with brain tissue donation, to R. Hills and J. Hurt for technical assistance, to S. West and I. Thies for secretarial assistance.

References

- Alzheimer A (1907) Über eine eigenartige Erkrankung der Hirnrinde. *Allg Z Psychiatr Psychiatr Gerich Med* 64: 146–148
- Ariagada PV, Growdon JH, Hedley-Whyte ET, Hyman BT (1992) Neurofibrillary tangles but not senile plaques parallel duration and severity of Alzheimer's disease. *Neurology* 42: 631–639
- Blocq P, Marinesco G (1892) Sur les lesions et la pathogenie de l'épilepsie dite essentielle. *Sem Med (Paris)* 12: 445–446
- Bondareff W, Wischik CM, Novak M, Amos WB, Klug A, Roth M (1990) Molecular analysis of neurofibrillary degeneration in Alzheimer disease: an immunohistochemical study. *Am J Pathol* 137: 711–723
- Bondareff W, Harrington C, Wischik CM, Hauser DL, Roth M (1994) Immunohistochemical staging of neurofibrillary degeneration in Alzheimer disease. *J Neuropathol Exp Neurol* 53: 158–164
- Bondareff W, Harrington C, Wischik CM, Hauser DL, Roth M (1995) Absence of abnormal hyperphosphorylation of tau in intracellular tangles in Alzheimer disease. *J Neuropathol Exp Neurol* 5: 657–663
- Braak H, Braak E (1991) Neuropathological staging of Alzheimer-related changes. *Acta Neuropathol* 82: 259
- Campbell SK, Switzer RC, Martin TL (1987) Alzheimer's plaques and tangles: a controlled and enhanced silver-staining method. *Soc Neurosci Abstr* 3: 687
- Chui HC, Victoroff JJ, Margolin D, Jagust W, Shankle R, Katzman R (1992) Criteria for the diagnosis of ischemic vascular dementia proposed by the State of California Alzheimer's Disease and Treatment Centers. *Neurology* 42: 473–480
- Esiri MM, Pearson RCA, Powell TPS (1986) The cortex of the primary auditory area in Alzheimer's disease. *Brain Res* 366: 385–387
- Esiri MM, Pearson RC, Steele JE, Bowen M, Powell TPS (1990) A quantitative study of the neurofibrillary tangles and the choline acetyl-transferase activity in the cerebral cortex and the amygdala in Alzheimer's disease. *J Neurol Neurosurg Psychiatry* 53: 161–165
- Gellerstedt N (1933) Zur Kenntnis der Hirnveränderungen bei der normalen Altersinvolution. *Uppsala Lak Forh NF* 38
- Gertz H-J, Xuereb JH, Huppert FA, Brayne C, Kruger H, McGee MA, Paykel ES, Harrington CR, Mukaetova-Ladinska EB, O'Connor DW, Wischik CM (1996) The relationship between clinical dementia and neuropathological staging (Braak) in a very elderly community sample. *Eur Arch Psychiatry Clin Neurosci* 246: 132–136
- Hirano A, Zimmerman HM (1962) Alzheimer's neurofibrillary changes. *Arch Neurol* 7: 227–234
- Mena R, Edwards P, Perez-Olvera O, Wischik CM (1995) Monitoring pathological assembly of tau and β -amyloid proteins in Alzheimer's disease. *Acta Neuropathol* 89: 50–56
- Mukaetova-Ladinska EB, Harrington CR, Roth M, Wischik C (1993) Biochemical and anatomical redistribution of tau protein in Alzheimer's disease. *Am J Pathol* 143: 565–578
- Nagy Z, Esiri MM, Jobst KA, Morris JH, King EM-F, McDonald B, Litchfield S, Smith A, Barnetson L, Smith AD (1995) Relative roles of plaques and tangles in the dementia of Alzheimer's disease: correlations using three sets of neuropathological criteria. *Dementia* 6: 21–31
- O'Connor DW, Pollitt PA, Hyde JB, Fellows L, Miller ND, Brook CPB, Reiss BB, Roth M (1989) The prevalence of dementia as measured by the Cambridge Mental Disorders of the Elderly Examination. *Acta Psychiatr Scand* 79: 190–198
- Paykel ES, Brayne C, Huppert FA, Gill C, Barkley C, Gehlhaar E, Beardsall L, Girling DM, Pollitt P, O'Connor D (1994) Incidence of dementia in an over 75 population in the United Kingdom. *Arch Gen Psychiatry* 51: 325–332
- Perusini G (1910) Über klinische und histologische eigenartige psychische Erkrankungen des späteren Lebensalters. In: Nissl F, Alzheimer A (eds) *Histologische und histopathologische Arbeiten*, 3rd edn. Fischer, Jena, pp 297–351
- Roth M, Huppert FA, Tym E, Mountjoy CQ (1988) CAMDEX. Cambridge University Press, Cambridge
- Simchowicz T (1991) Histologische Studien über die senile Demenz. In: Nissl F, Alzheimer A (eds) *Histologische und histopathologische Arbeiten über die Grosshirnrinde mit besonderer Berücksichtigung der pathologischen Anatomie der Geisteskrankheiten*, 4th edn. Fischer, Jena, pp 267–444
- Tomlinson BE, Henderson G (1976) Some quantitative cerebral findings in normal and demented old people. In: Terry RD, Gershon S (eds) *Neurobiol. Aging*, 3rd edn. Raven Press, New York, pp 183–204
- Wilcock GK, Esiri MM (1982) Plaques, tangles and dementia of Alzheimer's type. *J Neurol Sci* 56: 343–356

